

ELECTROPHYSIOLOGICAL INVESTIGATIONS IN THE LOCKED-IN SYNDROME: A CASE REPORT

Zaitoon M. Shivji, RET, RT.EMG,
Leopold J. Streletz, M.D., Saleh Baeesa, M.B., FRCS(C),
and John Girvin, M.D., FRCS(C)

*Neurophysiology Laboratory
Department of Neurosciences
King Faisal Specialist Hospital and Research Center
Jeddah, Kingdom of Saudi Arabia*

ABSTRACT. *A 17-year-old boy was involved in an accident the details of which are not well known. It was felt that he might have had some type of questionable arrest from which he was resuscitated and intubated and assessed as being in "deep coma" by the referring hospital. At our hospital, he was found to be completely unresponsive below the eyes. The only evidence of any neurological function over his body was reflex movement of the toes in plantar flexion. Caloric testing, magnetic resonance imaging (MRI), EEG, and evoked potentials (EPs) were some of the clinical investigations. MRI disclosed abnormality from the pontomedullary junction to C6-C7. This young man exhibited the features of a classic "locked-in" syndrome from a type of traumatic event, which has not previously been reported. EEG and EPs can be very important diagnostic tests in the "locked-in" syndrome, as well as providing important monitoring regarding prognosis.*

KEY WORDS. *Alpha-coma, brainstem lesion, EEG, evoked potentials, "locked-in" syndrome.*

INTRODUCTION

The seat of consciousness has been recognized as being in the brain since early times. The Egyptians were among the ancients to have recognized this (Wilkins

Received September 12, 2002. Accepted for publication: March 7, 2003.

1964); however, the anatomical structures and physiological processes involved in awareness were not clarified until the middle of the 20th century. The anatomy of arousal, we now know, requires the interplay of both the ascending reticular activating system (ARAS) of the midbrain and thalamus, and the cerebral hemispheres. The reticular components, the activation of which are necessary for arousal, reside in the midbrain tegmentum and the intralaminar nuclei of the thalamus. The midbrain may be considered as the driving center for consciousness when it receives activation by ascending sensory stimuli. Its loss results in a state in which the cortex is idling, waiting for further input (Bleck 1999). In the face of such loss, the EEG demonstrates "alpha coma," a state characterized by electrical activity that morphologically resembles, and at times appears similar to, the normal alpha activity but appears in unusual spatial distribution and is unreactive.

Arousal, or consciousness, is impaired when the normal activation of the midbrain and the diencephalon is distorted. Awareness implies that the individual is not only alert but also cognizant of self and the surroundings. The interaction of the cerebral cortex and the reticular system is required for the individual to demonstrate content of the conscious awareness. ARAS provides the arousal; the cerebral cortex provides the content of consciousness. Penfield, as early as 1957, noted that neuronal activity in higher brainstem structures and the cerebral cortex was continual in an ever-changing pattern. He also commented that this organized neuronal activity, with what he called "centrencephalic" integration, formed the basis of the conscious state. He pointed out then that the reticular formation was functionally inseparable from the cortex.

Cairns et al. (1941) coined the term "akinetic mutism" to describe the clinical state of a 15-year-old girl with an epidermoid cyst of the third ventricle. She had the ability to move but "usually" could not be stimulated to do so (i.e., akinetic). She did not speak (i.e., mute) but followed external stimuli with her eyes. They interpreted the state as resulting from pressure on the surrounding diencephalon, interrupting the connections between the diencephalon and the cerebral cortex. When the cyst was aspirated, not only did the patient return to normal, but the EEG activity, which consisted of bursts of high voltage sinusoidal slow waves in the akinetic mute state, also returned to normal. Cairns (1952) in reviewing the clinical aspects of consciousness from his personal experience drew also from observations of Penfield and Magoun to conclude that the brainstem and thalamus were necessary for consciousness, while the content, i.e., the conscious experience, was dependent upon the cerebral cortex.

The so-called "locked-in" syndrome was described during the latter part of the 20th century. Chatrian and colleagues (1964a) described neurological findings characteristic of the syndrome in a 59-year-old man who had had a severe head injury. His EEG pattern, "resembling wakefulness," was not considered to be commensurate with the clinical state of the patient, who was unresponsive and

decerebrate. They noted two previously reported such cases by Loeb and Poggio in 1953 and Lundervold and colleagues in 1956. From these three cases they felt that the lesion resulting in the appearance of an awake EEG with clinical unresponsiveness was at the pontomesencephalic junction. Marquardsen and colleagues (1964) described the electroencephalogram in acute vascular lesions involving the brainstem and drew attention to the fact that lesions affecting the upper brainstem will almost always result in abnormalities in the EEG, more particularly slowing. This was in contrast to lesions of the lower brainstem (pontomedullary), which often did not appreciably influence the EEG. The etiology of the majority of these types of cases consisted of vascular infarctions restricted to the brainstem, and more particularly the pons.

Plum and Posner (1966) coined the term "locked-in" to describe a patient with bilateral infarction of the basis pontis. Their patient was described as alert but having no voluntary motor activity other than vertical eye movements, with which he was able to reliably communicate.

Clinical Investigations in "Locked-In" Syndrome

EEG is more useful in supratentorial, than in infratentorial, lesions. The reported incidence of EEG abnormalities associated with brainstem lesions varies widely. The EEG changes with brainstem lesions may vary from being slight, consisting of diffuse or bilateral slowing, to being more striking, consisting of paroxysmal discharges and sharp activity, focal abnormalities or low-voltage fast activity. In general, normal EEG configurations have been considered compatible with small lesions, laterally and caudally situated in the brainstem, while there is a relatively high incidence of EEG abnormalities associated with large, medial and rostral infarcts. Cases of comatose patients with preserved EEG patterns characteristic of wakefulness were reported as early as the 1950s. Chase and colleagues (1968a), as well as others have shown that the dissociation between the resting EEG and clinical state is most striking in totally unresponsive patients with pontine lesions. They tend to have EEG activity that one would call "alpha rhythm" but which may have unusual spatial distribution and morphology and is unaffected by any kind of stimuli. This alpha frequency activity cannot accurately be referred to as "alpha rhythm" as it does not behave like the characteristic alpha rhythm as seen in normal subjects. The photic stimulation effect studied in a few patients (Chase et al. 1968b) has been reported as normal; sleep studies have been reported as normal, other than lacking the characteristics of REM sleep.

Evoked potentials (EPs), though of no definite diagnostic value in this population, can provide information concerning the functional state of the cerebral cortex, brainstem, and spinal cord. Somatosensory evoked potentials (SSEP) determine the functional integrity of the posterior columns of the spinal cord, the medial lemniscus

of the brainstem, the thalamus, and the frontoparietal sensorimotor cortex. In brainstem lesions, cortical potentials (N20) can be abolished while the cervical (N13) and Erb's point potentials are normal. Brainstem auditory evoked potentials (BAEP) correlate with brainstem function. Simultaneous latency increase of all components can be consistent with progressive ischemia of the posterior fossa, a decrease in cerebral perfusion pressure, or both. Feldman (1971) reported on the analysis and utility of various evoked potentials in his patient with "locked-in" syndrome. In the "locked-in" syndrome, the BAEP may be valuable in localizing the lesion in the brainstem (Gilroy et al, 1977).

The MRI is the preferred modality for imaging. The quality of resolution of the computed tomography (CT) scan is compromised by bone artifact and may be very unreliable in imaging pontine infarcts. The magnetic resonance angiography (MRA) is often helpful in characterizing the status of the vertebrobasilar artery and its branches. The understanding of MRA studies may be enhanced by transcranial Doppler sonography or catheter angiography.

CASE REPORT

A 17-year-old boy was a pedestrian who was struck by a car and questionably by a second vehicle, and was thrown to the ground "unconscious." From the history, he may have had a cardiopulmonary arrest and at one point was considered to be "pulseless." In the referring hospital he had had a CT scan, which was reported as showing blood in the ventricular system, and plain x-rays of the cervical spine showing what was interpreted as a questionable abnormality at the C6-C7 level. For management of the patient's unconscious state, he was transferred to a tertiary medical center. On admission the patient was obese, appeared to be totally unresponsive, had been placed in a neck collar, and exhibited no evidence of any spontaneous movement. He was being ventilated through an endotracheal tube.

Cranial nerve examination revealed very small, nearly pinpoint, unresponsive pupils. Cold water caloric testing resulted in a number of rather unpredictable movements, with an underlying initial interpretation of a background of tonic ipsilateral deviation. There were brisk, normal corneal reflexes. There was a suggestion of tone intermittently in the eyelids. There was no evidence of any other cranial nerve function. There was no evidence of any motor function except that of some abortive movement of the great toes into plantar flexion with stroking of the soles of the feet. It was primarily the variable alteration in tone in the eyelids, and the somewhat unexpected caloric responses of the eyes, that led the examiner to consider that the patient might not be in traumatic coma, but rather that he might represent a case of "locked-in" syndrome. This was verified with the appropriate questioning and the establishment of his use of eye movements for communication.

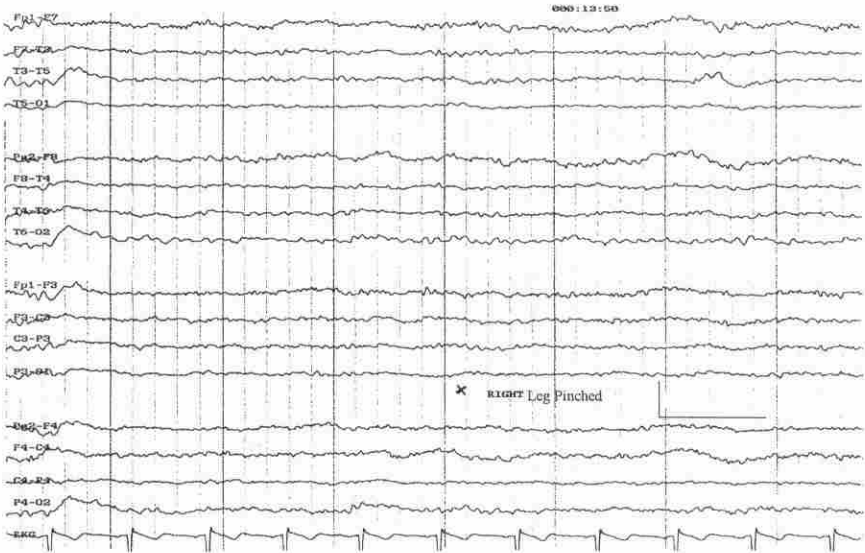

FIG. 1. The EEG revealed 9–10 Hz activity maximal posterior, with some diffuse non-specific slowing. Reactive to noise, not to tactile stimulation. The patient was very sleepy.

The patient was taught to communicate with eye movements, blinking once for “yes” and twice for a “no.” He was kept intellectually stimulated this way during his hospital stay.

Course in the Hospital

An MRI disclosed evidence of swelling of the scalp and an obvious abnormal heterogeneous signal in an enlarged lower brainstem. The latter was also present on the MRI of the cervical spinal cord along with disruption of the C6-C7 disc and an associated disruption of the posterior elements at the same level.

Within 24 hours of admission, the patient’s pupils become larger (2 mm), symmetrical, and normally responsive to light. A 21-channel EEG with the 10-20 method of electrode placement showed the then expected normality (Figure 1). The posterior rhythm was 8–10 Hz and reactive to noise and on eye opening and closing as requested. Tactile stimulation did not affect the EEG. Some underlying theta activity was widely distributed. The NREM sleep pattern was poorly defined. Brainstem auditory evoked potentials (BAEP) recorded from the mastoid electrode referred to the vertex, with unilateral stimulation, were reported as normal bilaterally. Bilateral median nerve somatosensory evoked potentials (SSEP),

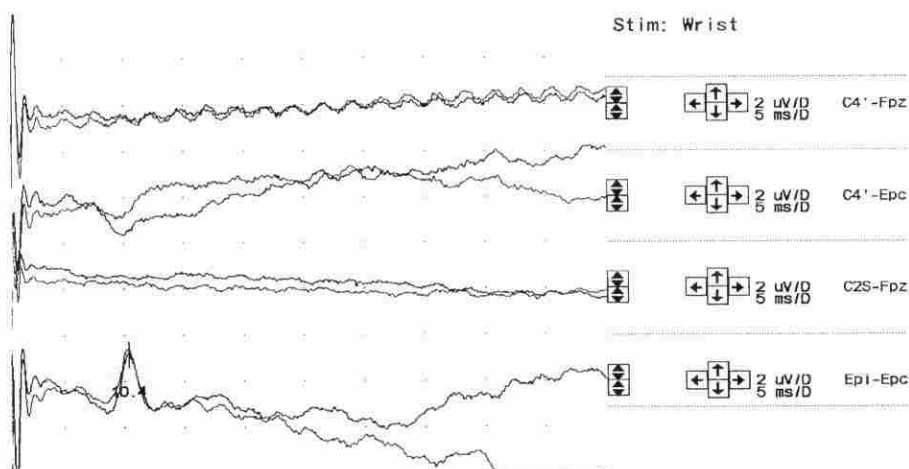


FIG. 2. SSEP of the left median nerve elicited only the N9 potential at Erb's point. N13, P14, and N20 were not identifiable. High-frequency noise is due to the bedside recording.

recorded from electrodes placed on the scalp in the region of the contralateral cortex (C3'/C4'), cervical spine level 2 (Cs2) and Erb's point (Ep), elicited only the Ep potential at Erb's point (Figures 2 and 3), but nothing identifiable from the cervical cord, the brainstem, or the cortex. This study correlated with his sensory deficit. A repeat MRI (Figure 4) and MRA disclosed the presence of intact vertebral arteries. On the 3rd post-traumatic day, the patient underwent an anterior cervical discectomy and instrumented fusion at the C6-C7 lesion. The patient remains "locked-in," now over a year since his original injury.

DISCUSSION

This young boy initially had no movements whatsoever; in follow-up has he never had any movement other than being able to blink. On the other hand, he did have suprabrulbar cranial nerve function in that he was able to hear and to communicate with extra ocular movements in all directions of gaze. There is no doubt that the patient's conscious state was much more difficult to describe in the initial 24-48 hours, but whether this was due to some type of acute cerebral (physiological) deafferentation or whether it was due to the effects of some type of mild cerebral concussion remains an open question.

He has remained in a state that would be best characterized clinically by a physiological or anatomical transection of his brainstem somewhere in the low pontine segment. Unlike many of the cases reported in the literature, he has never

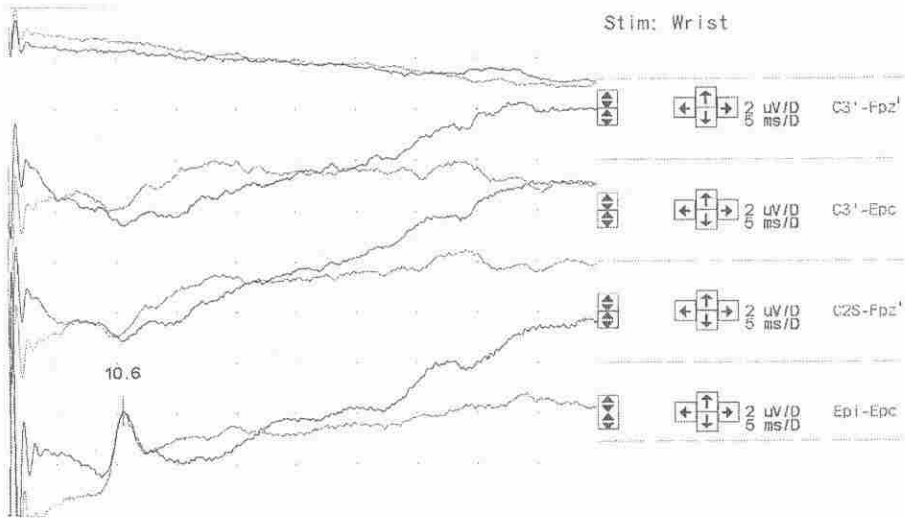


FIG. 3. SSEP of the right median nerve elicited only the N9 potential at Erb's point. N13, P14, and N20 were not identifiable. High-frequency noise is due to the bedside recording.

shown any recovery whatsoever of function below this level. The finding of the EEG activity in this patient closely resembles that found in wakefulness, in an otherwise unresponsive patient.

The "locked-in" patients, with basis pontis lesions, may initially appear comatose, with selective supranuclear motor de-efferentation producing quadriplegia and paralysis of lower cranial nerves and significant pontine dysfunction associated with pinpoint pupils. Usually the lesion causing the "locked-in" syndrome is such that the patient is left with only the capacity to use vertical eye movements and can be taught to communicate by blinking, or some sort of Morse code. It is of obvious ethical importance to distinguish the "locked-in" state from cases of coma, as the former, in contrast to the latter, involves a patient who is appropriately aware of self and the environment, with an intact mind. It is worth emphasizing that such patients should be immediately recognized to be conscious so that appropriate care, including appropriate ongoing vocal interaction with the patient (care to mind and body), can be established early in the course of the treatment to enrich their environment. Otherwise they may remain truly locked-in.

A patient with the "locked-in" syndrome, as noted, is completely locked in, except for the eye movements and yet usually has no intellectual deterioration despite the profound motor deficit. The reported incidence of EEG abnormalities associated with vascular lesions of the brainstem varies widely. An understanding of this "locked-in" state in man is difficult to study. Only careful analyses of such

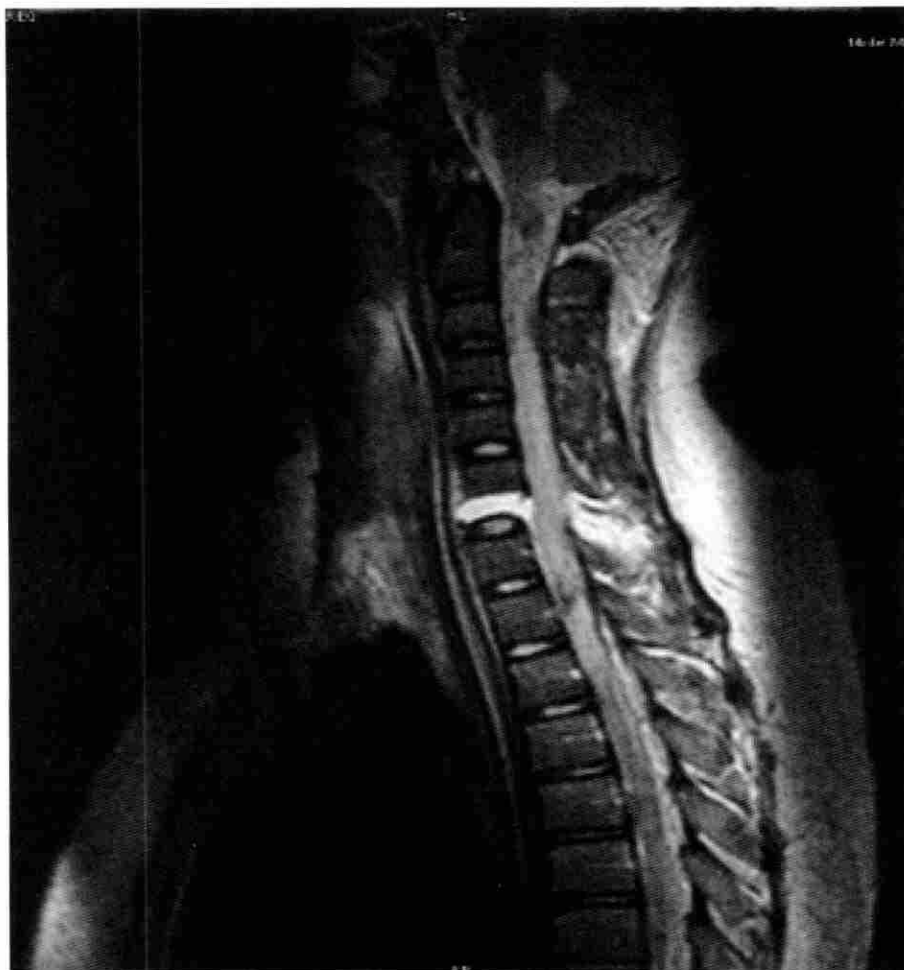

FIG. 4. MRI showing no evidence at all of any type of supratentorial lesion. There is disruption of the C6-C7 disc and an associated disruption in the posterior elements at the same level. The defect in the neuraxis, seen in the lower part of the brainstem, was evident throughout the cervical cord, extending down to the level of T1-T2.

states in humans will provide observations which allow for comparisons with experimental studies in animals. From the experimental studies in cats by Andersen and Andersson (1968), and others before them, it appears that the cortex contains neural networks that can generate spontaneous rhythms. Other observations have suggested that extracortical pacemakers normally drive the cortical activities. Bremer (1935) showed experimentally that the location of the EEG pacemaker lies

in the brainstem. He found that complete transection the midbrain of a cat ("cerveau isolé") resulted in electrical activity dominated by slow waves. If the transection was made lower, at the junction of the spinal cord and medulla ("encephale isolé"), the cortical activity was desynchronized, thus clearly showing that some structure in the lower brainstem was necessary for activating the cortex. Another experiment, by Lindsley et al. (1950), showed that a lesion in the reticular formation caused the animal to become somnolent and to develop rhythmic cortical activity, while a lesion outside the reticular formation, interrupting the lemniscal somatosensory pathways, did not have these effects. Sparing of the pontine tegmentum with its reticular formation is necessary for the appearance of normal EEG. In humans, the integrity of the rostral portion of the pons is essential for the maintenance of normal EEG activity.

Pontine lesions with quadriplegia, without midbrain involvement, may mimic coma, as in the "locked-in" syndrome, by significantly interrupting the efferent pathways from the cerebral cortex. Patients can move their eyes vertically and can blink because the supranuclear oculomotor pathways, lying rostral to the lesion, are spared. Lesions of the basis pontis with midbrain involvement disrupt the corticospinal tracts and abducens nuclei resulting in the loss of horizontal eye movements, and the facial nerve, resulting in the loss of horizontal eye movements and facial paralysis. When the midbrain ARAS is not involved, the patients may be awake and alert. A lesion in the pons, at or above the abducens nuclei, transecting the corticospinal and corticobulbar tracts would cause loss of all voluntary motor activity except vertical eye movements and convergence. An almost complete central transection of the pons, including the caudal tegmentum, could result in the same clinical state. The patients are unable to move their extremities but are conscious and able to communicate by eye movements. Some patients have decerebrate spasms in response to noxious stimulation. The "locked-in" state at times may mimic severe neuropathic disorders like the Guillain-Barre syndrome. An EEG is indicated in most patients with altered consciousness because history and examination are not always adequate to detect cases of non-convulsive status epilepticus, especially if the event causing the loss of consciousness is not clear.

SUMMARY

Altered awareness can result from either midbrain (pontomesencephalic) dysfunction, as in "locked-in" syndrome or bilateral hemispheric dysfunction. An unexpectedly normal EEG, with alpha blocking on passive eye opening and other stimuli, and normal sleep-wake cycling, should alert the observer to the likelihood of psychogenic unresponsiveness. On the other hand a normal appearing EEG, in a patient judged to be comatose, is pathognomonic of a brainstem lesion (Sharbrough 1999).

The clinical electrophysiological investigations associated with different levels of brainstem lesions may be helpful in evaluating patients with altered states of consciousness, and indeed may be of definitive diagnostic significance such as the current case of "locked-in" syndrome. Further, they may be early prognostic predictors for long term clinical outcome. We feel more electrophysiological studies and monitoring in "locked-in" syndrome are warranted. Perhaps the recent move toward increased electrophysiologic monitoring in the intensive care unit will shed more light on this fascinating clinical condition.

Address reprint requests to: Zaitoon M. Shivji, RET, RT.EMG, 4113 Laurel Ridge, Weston, FL 33331.

REFERENCES

- Anderson P, Anderson SA. The physiological basis of the alpha rhythm. New York: Appleton-Century-Crofts; 1968.
- Bleck TP. Levels of consciousness and attention. In: Goetz CG, Pappert EJ, editors. Textbook of clinical neurology. Philadelphia: WB Saunders Company; 1999. p. 2-16.
- Bremer F. Cerveau "isolé" et physiologie du sommeil. C R Soc Biol 1935; 118:1235.
- Cairns H. Disturbances of consciousness with lesions of the brain-stem and diencephalon. Brain 1952; 75:109-46.
- Cairns H, Olfield RC, Pennybacker JB, Whitteridge SD. Akinetic mutism with an epidemoid cyst of the third ventricle. Brain 1941; 64:273-290.
- Chase TN, Moretti L, Pinsky AL. Clinical and electro-encephalographic manifestations of vascular lesions of the pons. Neurology 1968; 18:357-68.
- Chatrian GE, White LE, Shaw C. EEG pattern resembling wakefulness in unresponsive decerebrate state following traumatic brain-stem infarct. Electroencephalogr Clin Neurophysiol 1964; 16:285-89.
- Gilroy J, Lynn GE, Ristow GE. Auditory evoked brain stem potentials in a case of "locked-in" syndrome. Arch Neurol 1977; 34:492-95.
- Feldman MH. Physiological observations in a chronic case of "locked-in" syndrome. Neurology 1971; 21:459-78.
- Lindsley DB, Schreiner LH, Knowles WB, Magoun HW. Behaviour and EEG changes following chronic brain stem lesions in the cat. Electroencephalogr Clin Neurophysiol 1950; 2:483.
- Marquardsen J, Harvald B. The electroencephalogram in acute vascular lesions of the brainstem and the cerebellum. J Acta Neurol Scand 1964; 40:58-68.
- Nordgren RE, Markesbery WR, Fukuda K, Reeves AJ. Seven cases of cerebromedullospinal disconnection: the "locked-in" syndrome. Neurology 1971; 21:1140-48.
- Penfield W. Consciousness and centrencephalic organization. Premier Congress International Des Sciences Neurologiques. Bruxelles, 21-28 July 1957; 7-18.
- Plum F, Posner JB. The diagnosis of stupor and coma. Vol. I Contemporary neurology series. Philadelphia: F. A. Davis Co 1966; p. 286.
- Sharbrough FW. Nonspecific abnormal EEG patterns. In: Niedermeyer E, Lopes da Silva F, editors. Electroencephalography. 4th ed. Baltimore: Williams & Wilkins; 1999 p. 221-22.
- Wilkins RH. Neurosurgical Classic-XVII - Edwin Smith Surgical Papyrus. J Neurosurg, March 1964; pages 240-44.

